

REVIEW ARTICLE

CURRENT CONCEPTS

Use of the Electrocardiogram
in Acute Myocardial Infarction

Peter J. Zimetbaum, M.D., and Mark E. Josephson, M.D.

THE ELECTROCARDIOGRAM REMAINS A CRUCIAL TOOL IN THE IDENTIFICATION and management of acute myocardial infarction. A detailed analysis of patterns of ST-segment elevation may influence decisions regarding the use of reperfusion therapy. The early and accurate identification of the infarct-related artery on the electrocardiogram can help predict the amount of myocardium at risk and guide decisions regarding the urgency of revascularization. Electrocardiographic signs of reperfusion represent an important marker of microvascular blood flow and consequent prognosis. The electrocardiogram is also crucial for identifying new conduction abnormalities and arrhythmias that influence both short- and long-term outcome. In this review, we discuss approaches to the interpretation of the electrocardiogram in the clinical management of patients during the first 24 hours after a myocardial infarction.

From the Cardiovascular Division, Department of Medicine, Beth Israel Deaconess Medical Center, Boston. Address reprint requests to Dr. Zimetbaum at the Division of Cardiology, Beth Israel Deaconess Medical Center, 1 Deaconess Rd., Boston, MA 02215, or at pzimetba@bidmc.harvard.edu.

N Engl J Med 2003;348:933-40.

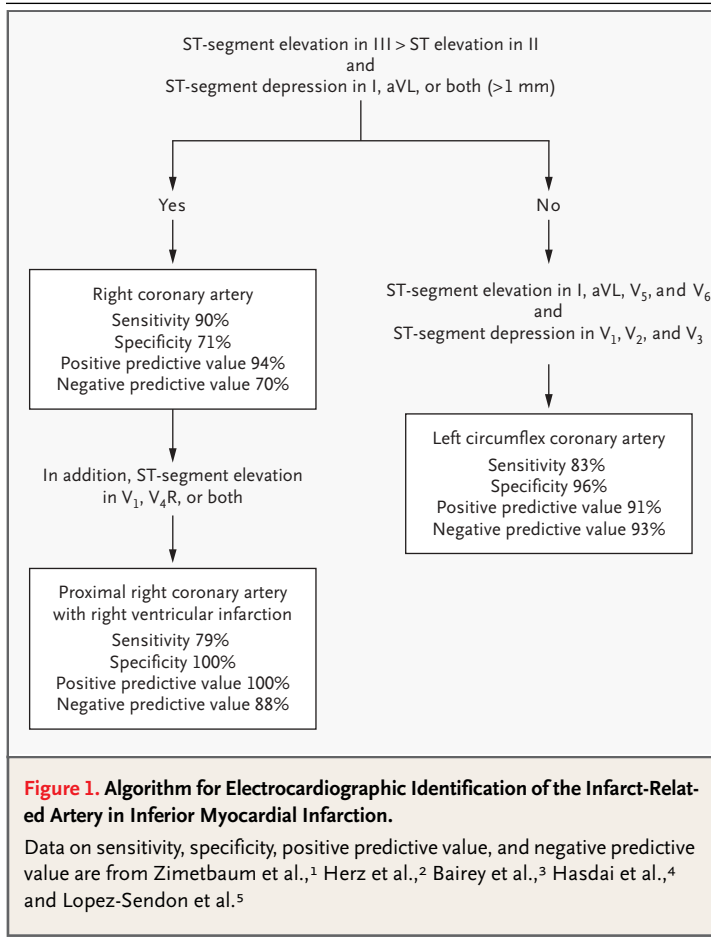
Copyright © 2003 Massachusetts Medical Society.

IDENTIFICATION OF THE INFARCT-RELATED ARTERY

The specificity of the electrocardiogram in acute myocardial infarction is limited by large individual variations in coronary anatomy as well as by the presence of preexisting coronary artery disease, particularly in patients with a previous myocardial infarction, collateral circulation, or previous coronary-artery bypass surgery. The electrocardiogram is also limited by its inadequate representation of the posterior, lateral, and apical walls of the left ventricle. Despite these limitations, the electrocardiogram can help in identifying proximal occlusion of the coronary arteries, which results in the most extensive and most severe myocardial infarctions.

INFERIOR MYOCARDIAL INFARCTION

The culprit vessel in inferior myocardial infarction may be either the right coronary artery (in 80 percent of the cases) or the left circumflex artery. Greater ST-segment elevation in lead III than in lead II and ST-segment depression of more than 1 mm in leads I and aVL suggest involvement of the right coronary artery rather than the left circumflex artery (Fig. 1).¹ ST-segment elevation in lead III is greater than that in lead II in the presence of infarction involving the right coronary artery because the ST-segment vector is directed toward the right (lead III). The added finding of ST-segment elevation in lead V₁ suggests proximal occlusion of the right coronary artery with associated right ventricular infarction.² Conversely, infarction involving the left circumflex artery produces an ST-segment vector directed toward the left (lead II). In this case, ST-segment elevation in lead III is not greater than that in lead II, and there is an isoelectric or elevated ST segment in lead aVL.³ ST-segment depression in leads V₁ and V₂ with ST-segment elevation in the inferior leads also suggests involvement of the left circumflex vessel, but this pattern may also be seen in infarction caused by occlusion of a dominant right coronary artery.⁴ In either circumstance, ST-segment depression in leads V₁ and V₂ suggest con-



comitant infarction of the posterior wall of the left ventricle.

RIGHT VENTRICULAR MYOCARDIAL INFARCTION

Right ventricular myocardial infarction is always associated with occlusion of the proximal segment of the right coronary artery. The most sensitive electrocardiographic sign of right ventricular infarction is ST-segment elevation of more than 1 mm in lead V₄R with an upright T wave in that lead. This sign is rarely present more than 12 hours after the infarction. As discussed above, ST-segment elevation in lead V₁ in association with ST-segment elevation in leads II, III, and aVF (with greater elevation in lead III than in lead II) is highly correlated with the presence of right ventricular infarction^{1,5} (Fig. 1).

MYOCARDIAL INFARCTION OF THE ANTERIOR WALL

In myocardial infarction of the anterior wall, ST-segment elevation in leads V₁, V₂, and V₃ indicates

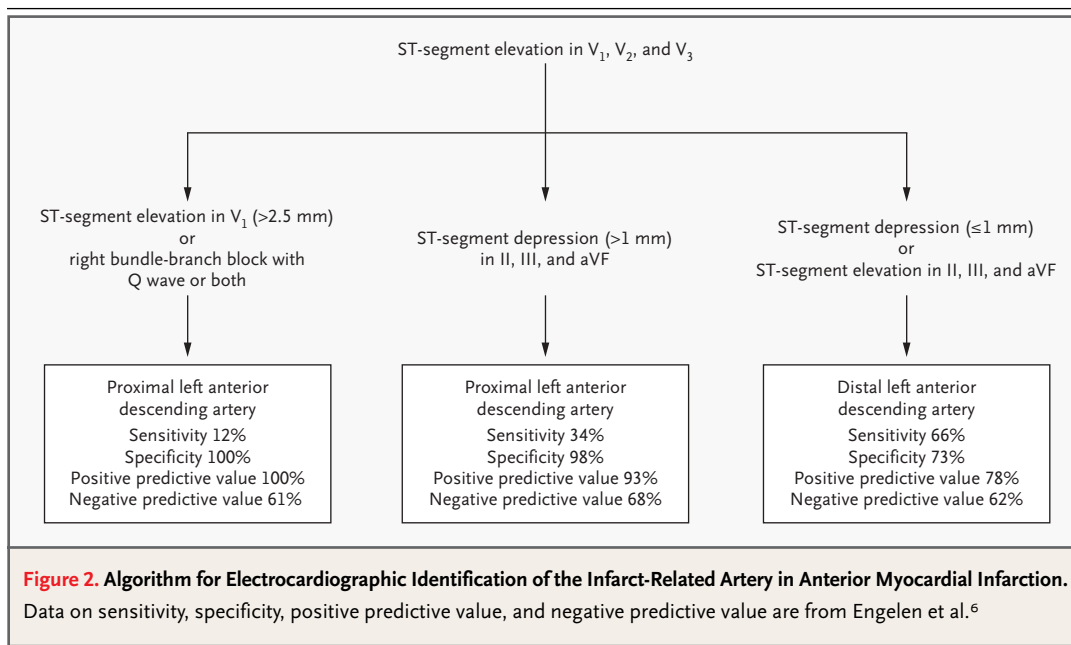
occlusion of the left anterior descending coronary artery. ST-segment elevation in these three leads and in lead aVL in association with ST-segment depression of more than 1 mm in lead aVF indicates proximal occlusion of the left anterior descending artery (Fig. 2).^{6,7} In this case, the ST-segment vector is directed upward, toward leads V₁, aVL, and aVR, and away from the inferior leads. ST-segment elevation in leads V₁, V₂, and V₃ without significant inferior ST-segment depression suggests occlusion of the left anterior descending artery after the origin of the first diagonal branch.⁶ ST-segment elevation in leads V₁, V₂, and V₃ with elevation in the inferior leads suggests occlusion of the left anterior descending artery distal to the origin of the first diagonal branch, in a vessel that wraps around to supply the inferoapical region of the left ventricle.⁶ New right bundle-branch block with a Q wave preceding the R wave in lead V₁ is a specific but insensitive marker of proximal occlusion of the left anterior descending artery in association with anteroseptal myocardial infarction⁶ (Fig. 2).

LEFT BUNDLE-BRANCH BLOCK

Spontaneous or pacing-induced left bundle-branch block can obscure the electrocardiographic diagnosis of acute myocardial infarction. In the presence of left bundle-branch block or a right ventricular paced rhythm, right ventricular activation precedes left ventricular activation; this activation of the infarcted left ventricle occurs later and is obscured within the QRS complex. Thus, Q waves cannot be used to diagnose infarction. An indicator of myocardial infarction in the presence of left bundle-branch block is primary ST change — that is, ST deviation in the same (concordant) direction as the major QRS vector. Concordant ST changes in the presence of left bundle-branch block include ST-segment depression of at least 1 mm in lead V₁, V₂, or V₃ or in lead II, III, or aVF and elevation of at least 1 mm in lead V₅. Extremely discordant ST deviation (>5 mm) is also suggestive of myocardial infarction in the presence of left bundle-branch block.⁸

ELECTROCARDIOGRAPHIC PREDICTORS OF REPERFUSION

The management of acute myocardial infarction is targeted toward restoration of blood flow in the infarct-related artery. There is increasing evidence that the presence of normal epicardial blood flow does not always correlate with microvascular perfusion



of the myocardial tissue.⁹ The absence of tissue perfusion is the most potent predictor of impaired ventricular function and the risk of death after myocardial infarction.⁹ Conversely, resolution of ST-segment elevation is believed to be an excellent marker of tissue perfusion, and the degree of resolution has proved to be a powerful indicator of short-term (30-day) and long-term (1-year) prognosis.^{10,11} Assessment of ST-segment resolution is also useful for guiding reperfusion therapy: the absence of ST-segment resolution during the first 90 minutes after the administration of fibrinolytic medications should prompt consideration of rescue angioplasty. A reduction in ST-segment elevation by more than 70 percent in the leads with maximal elevation is associated with the most favorable outcomes.¹²⁻¹⁴

In the future, therapies that promote microvascular blood flow after restoration of blood flow in the infarct-related artery may become available. The simplicity of assessing ST-segment resolution will probably make this step an important component of the decision to administer such therapies.

Other electrocardiographic markers of reperfusion include T-wave inversion within four hours after myocardial infarction. T-wave inversion that occurs during the first few hours of reperfusion therapy is a highly specific sign of reperfusion.¹⁵ T-wave inversion that develops more than four hours after the start of reperfusion therapy is consistent with the normal electrocardiographic evo-

lution of myocardial infarction and does not indicate that reperfusion has occurred. An accelerated idioventricular rhythm (defined as a heart rate of 60 to 120 beats per minute initiated by a late, coupled, ventricular premature depolarization) is a highly specific marker of reperfusion.^{16,17} This rhythm is benign and should not be suppressed with medication. Isolated ventricular premature depolarizations may also be seen with reperfusion. Polymorphic ventricular tachycardia and ventricular fibrillation may be seen with reperfusion but are rare and should raise the suspicion of ongoing arterial occlusion.

ARRHYTHMIAS AND CONDUCTION DISEASE IN ACUTE MYOCARDIAL INFARCTION

Conduction abnormalities, including bundle-branch block or varying forms of heart block during acute myocardial infarction, may be associated with a poor prognosis.¹⁸⁻²³ The incidence of conduction abnormalities associated with acute myocardial infarction has diminished in the era of early revascularization therapy, but the mortality and morbidity associated with these abnormalities remain unchanged.²³ The presence and clinical significance of different types of bradyarrhythmias and conduction disease depend on the location of the infarct and the mass of the involved myocardium.

An understanding of the bradyarrhythmias and

conduction disease that may be associated with acute myocardial infarction requires a review of the anatomy and blood supply of the conduction system. The sinus node is supplied by the right coronary artery in 60 percent of people and by the left circumflex artery in 40 percent. The atrioventricular node is supplied by the right coronary artery in 90 percent of people and by the left circumflex artery in 10 percent. The bundle of His is supplied by the atrioventricular nodal branch of the right coronary artery, with a small contribution from the septal perforators of the left anterior descending artery.¹¹ The bundle of His divides into the right and left bundle branches in the interventricular septum. The right bundle branch receives most of its blood from septal perforators of the left anterior descending artery. There may also be collateral blood supply from the right coronary artery or left circumflex artery. The proximal left bundle branch divides into the left anterior fascicle and the left posterior fascicle. The left anterior fascicle is supplied by septal perforators from the left anterior descending artery and is particularly susceptible to ischemia or infarction. The proximal portion of the left posterior fascicle is supplied by the atrioventricular nodal artery (i.e., the right coronary artery) and by septal perforators of the left anterior descending artery. The distal por-

tion of the posterior fascicle has a dual blood supply from the anterior and posterior septal perforating arteries.

INFERIOR MYOCARDIAL INFARCTION

Conduction abnormalities in association with inferior myocardial infarction can occur immediately or hours or days after infarction. Sinus bradycardia or varying degrees of atrioventricular block (including complete heart block) can occur within the first two hours after an acute inferior myocardial infarction as a result of heightened vagal tone. Such conditions often resolve within 24 hours,²⁴ and they are very responsive to atropine. Later in the course of inferior myocardial infarction, progressive conduction delay and block may occur. Their spontaneous resolution is regressive, as third-degree atrioventricular block becomes second-degree and then first-degree block and finally resolves, with normal conduction ensuing. This phase of atrioventricular conduction problems appears to be related to edema and local accumulation of adenosine.²⁵ It is less responsive to atropine than the acute phase and may respond to aminophylline.²⁵

The atrioventricular node is the site of conduc-

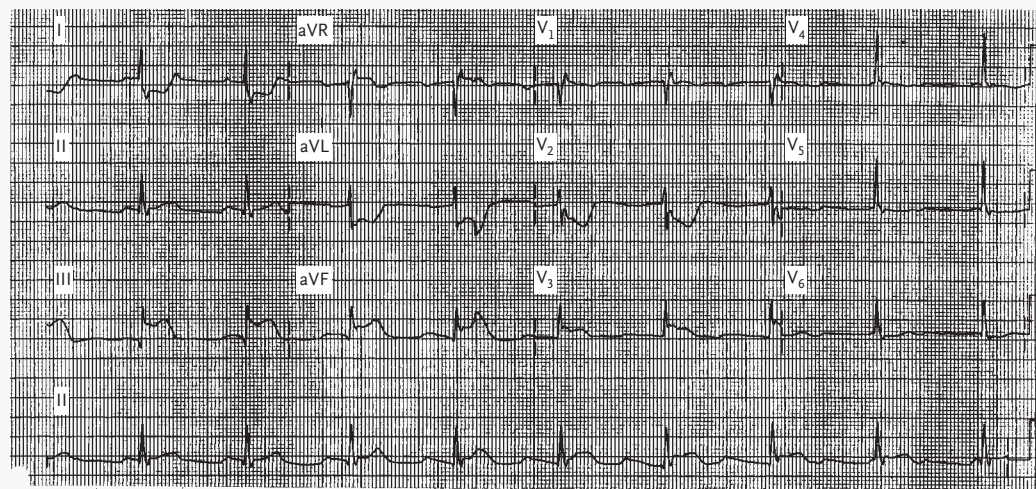


Figure 3. Electrocardiogram Showing Inferior Myocardial Infarction Associated with Complete Heart Block with a Narrow Escape Rhythm.

There is ST-segment elevation in lead III that is greater than the ST-segment elevation in lead II, marked ST-segment depression in leads I and aVL, and ST-segment elevation in lead V₁ — all consistent with the occurrence of proximal occlusion of the right coronary artery in association with right ventricular infarction. If the patient is in hemodynamically stable condition, a temporary pacemaker is not required.

tion disturbances in inferior myocardial infarction; therefore, complete atrioventricular block is generally associated with a narrow complex escape rhythm of between 40 and 60 beats per minute (Fig. 3). It is usually asymptomatic but may be associated with hemodynamic instability due to loss of atrioventricular synchrony. It is generally transient and resolves within five to seven days but may persist for up to two weeks. A ventricular escape rhythm with a widened QRS complex may signify the presence of block below the atrioventricular node and impaired collateral circulation to an occluded left anterior descending artery.

The management of conduction abnormalities associated with myocardial infarction depends on the associated symptoms. As noted above, bradyarrhythmias during the first few hours after an acute inferior myocardial infarction are responsive to atropine; conduction disease that begins or persists after the first 24 hours of myocardial infarction is not responsive to atropine. If the patient has hemo-

dynamic instability, worsening ischemia, or ventricular arrhythmias, a temporary pacemaker should be used. Placement of temporary pacing wires in the right atrium (or coronary sinus) and right ventricle allows restoration of atrioventricular synchrony and improves hemodynamic function. In most instances, conduction abnormalities associated with acute inferior myocardial infarction resolve within two weeks, and permanent pacing is not required (Table 1).

ANTERIOR MYOCARDIAL INFARCTION

As opposed to inferior myocardial infarction, conduction disease associated with anterior myocardial infarction is not related to heightened vagal tone but instead to necrosis of the intramyocardial conduction system. This condition occurs almost exclusively in the presence of proximal occlusion of the left anterior descending artery and septal necrosis. PR prolongation in acute anterior myocardial infarction is rarely due to atrioventricular nodal ischemia, since in most people the atrioventricular node is

Table 1. Guidelines of the American College of Cardiology and the American Heart Association for Temporary or Permanent Implantation of Pacemakers in Patients with Acute Myocardial Infarction.*

Class†	Indications for Temporary Pacing	Indications for Permanent Pacing
I	Asystole Symptomatic bradycardia (including sinus bradycardia or Mobitz type I block with hypotension) Bilateral BBB (alternating BBB or right BBB alternating with LAFB or LPFB) Bifascicular block that is new or of indeterminate age (right BBB with LAFB or LPFB or left BBB) with a prolonged PR interval Mobitz type II second-degree AV block	Persistent second-degree AV block in the His–Purkinje system, with bilateral BBB or third-degree AV block within or below the His–Purkinje system after myocardial infarction Transient advanced (second- or third-degree) infranodal AV block and associated BBB‡ Persistent and symptomatic second- or third-degree AV block
IIa	Right BBB and LAFB or LPFB that is new or of indeterminate age Right BBB with a prolonged PR interval Left BBB that is new or of indeterminate age Recurring sinus pauses not responsive to atropine	None
IIb	Bifascicular block of indeterminate age Isolated right BBB that is new or of indeterminate age	Persistent second- or third-degree AV block at the level of the AV node
III	Prolonged PR interval Type I second-degree AV block with normal hemodynamics Accelerated idioventricular rhythm BBB or fascicular block known to exist before acute myocardial infarction	Transient AV conduction disturbances in the absence of intraventricular conduction defects Transient, isolated AV block in the presence of isolated LAFB Acquired LAFB in the absence of AV block Persistent first-degree AV block in the presence of BBB that is old or of indeterminate age

* The information is adapted from Ryan et al.²⁶ and Gregoratos et al.²⁷ AV denotes atrioventricular, BBB bundle-branch block, LAFB left anterior fascicular block, and LPFB left posterior fascicular block.

† Class designations refer to the level of evidence supporting the effectiveness of the procedure or treatment, where class I indicates that the evidence is very strong and class III that it is absent or that the procedure is not useful and may be harmful.

‡ An electrophysiological study may be useful to determine the site of the block.

supplied by the right coronary artery. More commonly, necrosis of the septum is associated with slight PR prolongation (usually <0.25 second) due to involvement of the conducting system below the atrioventricular node. In this situation, PR prolongation is often associated with a wide QRS complex (>0.12 second) with a right bundle-branch block pattern.

Second-degree atrioventricular block with anterior myocardial infarction is usually Mobitz type II block secondary to block in the His–Purkinje system. Complete heart block results from extensive necrosis of the ventricular septum. It usually occurs abruptly during the first 24 hours after myocardial infarction and is almost always preceded by the development of right bundle-branch block with right- or left-axis deviation (Fig. 4). In right bundle-branch block associated with anterior myocardial infarction, a Q wave precedes the R wave in lead V₁ (QR in lead V₁).

Both the left anterior fascicle and the right bundle branch are supplied by the septal branches of the proximal left anterior descending artery. Anteroseptal infarctions may be associated with the development of new right bundle-branch block, with left anterior (or, less commonly, left posterior) fascicular block. The development of bifascicular

block with anteroseptal infarction is associated with as much as a 30 percent excess risk of complete heart block.^{18,21} The addition of PR prolongation to bifascicular block further increases this risk of complete heart block. The mortality associated with complete heart block in anterior myocardial infarction, with or without preceding right bundle-branch block and left fascicular block, may be as high as 80 percent.¹⁸ This mortality rate is largely related to progressive pump failure as a result of extensive myocardial necrosis. A temporary pacemaker should be placed in patients with anterior infarction and new right bundle-branch block (QR in lead V₁) with left anterior or left posterior fascicular block if there is associated PR prolongation (Table 1). Another indication for temporary pacing during anterior myocardial infarction is alternating right and left bundle-branch block.

TACHYARRHYTHMIAS

Tachyarrhythmias that occur during acute myocardial infarction may result from reperfusion, altered autonomic tone, or hemodynamic instability. Sinus tachycardia generally results from heightened adrenergic tone and is usually a manifestation of he-

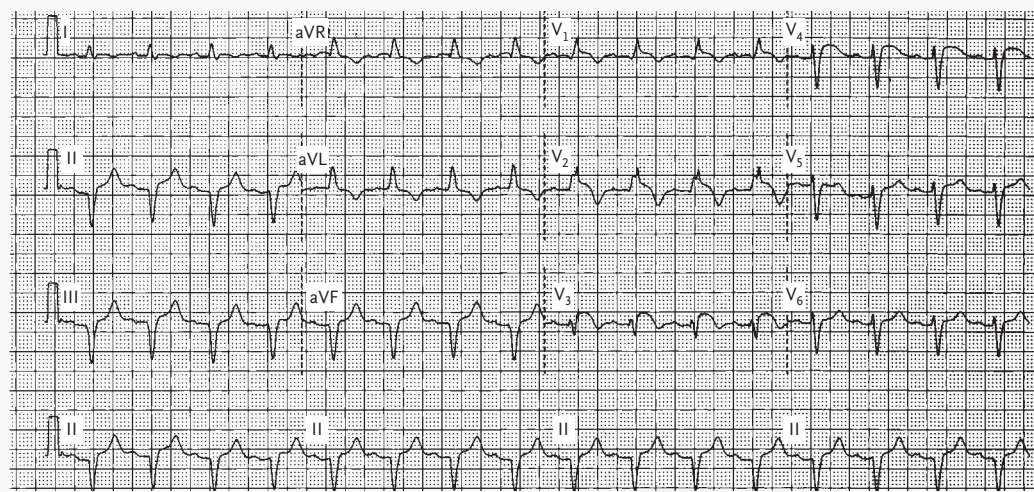


Figure 4. Electrocardiogram Showing Anterior Myocardial Infarction Associated with Right Bundle-Branch Block with a QR Pattern and ST-Segment Elevation.

Left anterior fascicular block and slight PR prolongation are also present. Together, the findings (which are new in comparison with an electrocardiogram obtained before myocardial infarction) suggest proximal occlusion of the left anterior descending artery. The patient has a substantial risk of complete heart block, and implantation of a temporary pacemaker is indicated.

modynamic failure. Atrial fibrillation may also occur in acute infarction and may result from increased vagal tone, increased left atrial pressure, atrial infarction, or pericarditis. Atrial fibrillation is associated with a worsened prognosis, regardless of the site of infarction.²⁸ Ventricular premature depolarizations are common during acute myocardial infarction but do not predict the subsequent development of sustained ventricular arrhythmias and should not be suppressed.²⁹ Sustained monomorphic ventricular tachycardia (with a heart rate above 150 beats per minute) is not generally associated with acute myocardial infarction unless there is a preexisting scar in the region that has become ischemic or a very large myocardial infarction.³⁰

Initially, ventricular fibrillation may be seen as an acute manifestation of ischemia; later (at two or three weeks), it may be seen as a consequence of progressive pump dysfunction. The presence of anterior myocardial infarction with right bundle-branch block and an ejection fraction of 35 percent or less is associated with recurrent ventricular tachycardia or fibrillation in the second and third weeks after myocardial infarction. In most instances, ventricu-

lar fibrillation in acute myocardial infarction is associated with lack of reperfusion of the infarct-related artery and should prompt evaluation for cardiac catheterization.³¹

CONCLUSIONS

Important information to guide management and determine prognosis can be derived from the electrocardiogram in patients with acute myocardial infarction. Electrocardiographic markers of proximal coronary-artery occlusion identify relatively large myocardial infarctions that benefit most from early and complete revascularization strategies, such as primary angioplasty. The degree of ST-segment resolution is a simple and powerful predictor of ventricular function and prognosis after myocardial infarction. Finally, the recognition of abnormalities of conduction that result from different types of myocardial infarction is essential to the proper management of these conditions.

We are indebted to William C. Quist, M.D., for his review of the anatomy of the cardiac conduction system.

REFERENCES

- Zimetbaum P, Krishnan S, Gold A, Carrozza JP II, Josephson M. Usefulness of ST-segment elevation in lead III exceeding that of lead II for identifying the location of the totally occluded coronary artery in inferior wall myocardial infarction. *Am J Cardiol* 1998;81:918-9.
- Herz I, Assali AR, Adler Y, Solodky A, Sclarovsky S. New electrocardiographic criteria for predicting either the right or left circumflex artery as the culprit coronary artery in inferior wall acute myocardial infarction. *Am J Cardiol* 1997;80:1343-5.
- Bairey CN, Shah K, Lew AS, Hulse S. Electrocardiographic differentiation of occlusion of the left circumflex versus the right coronary artery as a cause of inferior acute myocardial infarction. *Am J Cardiol* 1987;60:456-9.
- Hasdai D, Birnbaum Y, Herz I, Sclarovsky S, Mazur A, Solodky A. ST segment depression in lateral limb leads in inferior wall acute myocardial infarction: implications regarding the culprit artery and the site of obstruction. *Eur Heart J* 1995;16:1549-53.
- Lopez-Sendon J, Coma-Canella I, Alcasena S, Seoane J, Gamallo C. Electrocardiographic findings in acute right ventricular infarction: sensitivity and specificity of electrocardiographic alterations in right precordial leads V₄R, V₃R, V₁, V₂, and V₃. *J Am Coll Cardiol* 1985;6:1273-9.
- Engelen DJ, Gorgels AP, Cheriex EC, et al. Value of the electrocardiogram in localizing the occlusion site in the left anterior descending coronary artery in acute anterior myocardial infarction. *J Am Coll Cardiol* 1999;34:389-95.
- Tamura A, Kataoka H, Mikuriya Y, Nasu M. Inferior ST segment depression as a useful marker for identifying proximal left anterior descending artery occlusion during acute anterior myocardial infarction. *Eur Heart J* 1995;16:1795-9.
- Sgarbossa EB, Pinski SL, Barbagelata A, et al. Electrocardiographic diagnosis of evolving acute myocardial infarction in the presence of left bundle-branch block. *N Engl J Med* 1996;334:481-7. [Erratum, *N Engl J Med* 1996;334:931.]
- Ito H, Maruyama A, Iwakura K, et al. Clinical implications of the 'no reflow' phenomenon: a predictor of complications and left ventricular remodeling in reperfused anterior wall myocardial infarction. *Circulation* 1996;93:223-8.
- van 't Hof AW, Liem A, Suryapranata H, Hoorntje JC, de Boer MJ, Zijlstra F. Angiographic assessment of myocardial reperfusion in patients treated with primary angioplasty for acute myocardial infarction: myocardial blush grade. *Circulation* 1998;97:2302-6.
- Matetzky S, Novikov M, Gruberg L, et al. The significance of persistent ST elevation versus early resolution of ST segment elevation after primary PTCA. *J Am Coll Cardiol* 1999;34:1932-8.
- Schroder K, Wegscheider K, Zeymer U, Tebbe U, Schroder R. Extent of ST-segment deviation in a single electrocardiogram lead 90 min after thrombolysis as a predictor of medium-term mortality in acute myocardial infarction. *Lancet* 2001;358:1479-86.
- Poli A, Fetiveau R, Vandoni P, et al. Integrated analysis of myocardial blush ST-segment elevation recovery after successful primary angioplasty: real-time grading of microvascular reperfusion and prediction of early and late recovery of left ventricular function. *Circulation* 2002;106:313-8.
- Angeja BG, Gunda M, Murphy SA, et al. TIMI myocardial perfusion grade and ST segment resolution: association with infarct size as assessed by single photon emission computed tomography imaging. *Circulation* 2002;105:282-5.
- Wehrens X, Doevendans P, Ophuis TJ, Wellens H. A comparison of electrocardiographic changes during reperfusion of acute myocardial infarction by thrombolysis or percutaneous transluminal coronary angioplasty. *Am Heart J* 2000;139:430-6.
- Gressin V, Louvard Y, Pezzano M, Lardoux H. Holter recording of ventricular arrhythmias during intravenous thrombolysis for acute myocardial infarction. *Am J Cardiol* 1992;69:152-9.
- Gorgels AP, Vos MA, Letsch IS, et al. Usefulness of the accelerated idioventricular rhythm as a marker for myocardial necrosis and reperfusion during thrombolytic therapy

- in acute myocardial infarction. *Am J Cardiol* 1988;61:231-5.
18. Hindman MC, Wagner GS, JaRo M, et al. The clinical significance of bundle branch block complicating acute myocardial infarction. 1. Clinical characteristics, hospital mortality, and one-year follow-up. *Circulation* 1978;58:679-88.
19. *Idem*. The clinical significance of bundle branch block complicating acute myocardial infarction. 2. Indications for temporary and permanent pacemaker insertion. *Circulation* 1978;58:689-99.
20. Harpaz D, Behar S, Gottlieb S, Boyko V, Kishon Y, Eldar M. Complete atrioventricular block complicating acute myocardial infarction in the thrombolytic era. *J Am Coll Cardiol* 1999;34:1721-8.
21. Sgarbossa EB, Pinski SL, Topol EJ, et al. Acute myocardial infarction and complete bundle branch block at hospital admission: clinical characteristics and outcome in the thrombolytic era. *J Am Coll Cardiol* 1998;31:105-10.
22. Go AS, Barron HV, Rundle AC, Ornato JP, Avins AL. Bundle-branch block and in-hospital mortality in acute myocardial infarction. *Ann Intern Med* 1998;129:690-7.
23. Newby KH, Pisano E, Krucoff MW, Green C, Natale A. Incidence and clinical relevance of the occurrence of bundle-branch block in patients treated with thrombolytic therapy. *Circulation* 1996;94:2424-8.
24. Feigl D, Ashkenazy J, Kishon Y. Early and late atrioventricular block in acute inferior myocardial infarction. *J Am Coll Cardiol* 1984;4:35-8.
25. Bertolet BD, McMurtrie EB, Hill JA, Belardinelli L. Theophylline for the treatment of atrioventricular block after myocardial infarction. *Ann Intern Med* 1995;123:509-11.
26. Ryan TJ, Antman EM, Brooks NH, et al. 1999 update: ACC/AHA guidelines for the management of patients with acute myocardial infarction: executive summary and recommendations: a report of the American College of Cardiology/American Heart Association Task Force on Practice Guidelines (Committee on Management of Acute Myocardial Infarction). *Circulation* 1999;100:1016-30.
27. Gregoratos G, Abrams J, Epstein AE, et al. ACC/AHA/NASPE 2002 guideline update for implantation of cardiac pacemakers and antiarrhythmia devices: summary article: a report of the American College of Cardiology/American Heart Association Task Force on Practice Guidelines (ACC/AHA/NASPE Committee to Update the 1998 Pacemaker Guidelines). *Circulation* 2002;106:2145-61.
28. Eldar M, Canetti M, Rotstein Z, et al. Significance of paroxysmal atrial fibrillation complicating acute myocardial infarction in the thrombolytic era. *Circulation* 1998;97:965-70.
29. Antman EM, Berlin JA. Declining incidence of ventricular fibrillation in myocardial infarction: implications for the prophylactic use of lidocaine. *Circulation* 1992;86:764-73.
30. Mont L, Cinca J, Blanch P, et al. Predisposing factors and prognostic value of sustained monomorphic ventricular tachycardia in the early phase of acute myocardial infarction. *J Am Coll Cardiol* 1996;28:1670-6.
31. Berger PB, Ruocco NA, Ryan TJ, Frederick MM, Podrid PJ. Incidence and significance of ventricular tachycardia and fibrillation in the absence of hypotension or heart failure in acute myocardial infarction treated with recombinant tissue-type plasminogen activator: results from the Thrombolysis in Myocardial Infarction (TIMI) Phase II trial. *J Am Coll Cardiol* 1993;22:1773-9.

Copyright © 2003 Massachusetts Medical Society.

CLINICAL PROBLEM-SOLVING SERIES

The Journal welcomes submissions of manuscripts for the Clinical Problem-Solving series. This regular feature considers the step-by-step process of clinical decision making. For more information, please see <http://www.nejm.org/hfa/articles.asp>.